

CASE REPORT

Capillary haemangioma of the middle ear: a rare lesion difficult to evaluate

Emangioma capillare dell'orecchio medio: una rara lesione difficile da valutare

V. PISTORIO, A. DE STEFANO¹, A.G. PETRUCCI², V. ACHILLI

ENT Department, "Maggiore" Hospital of Lodi; ¹ ENT Institute, Dept. of Surgical, Experimental and Clinical Sciences, "G. d'Annunzio" University of Chieti-Pescara; ² Institute of Epidemiology and Public Health, "G. d'Annunzio" University of Chieti-Pescara, Italy

SUMMARY

Haemangiomas are benign vascular tumours relatively common in the head and neck district but very rare in the temporal bone. Depending on its clinical presentation, haemangioma can be mistaken for other vascular masses such as glomus tumour or other lesions of the middle ear. Unfortunately, clinical and radiological evaluation may be insufficient to make a pre-operative diagnosis and the diagnosis is often based upon intra-operative biopsy specimen findings.

KEY WORDS: Middle ear • Vascular tumour • Haemangioma • Glomus tumour

RIASSUNTO

Gli emangiomi sono tumori vascolari benigni relativamente comuni nel distretto testa-collo ma molto rari nell'osso temporale. In base alla sua presentazione l'emangioma può essere confuso con un'altra massa di origine vascolare, con un tumore glomico o con un'altra lesione dell'orecchio medio. Sfortunatamente la valutazione clinica e radiologica può essere insufficiente per fare una diagnosi preoperatoria, la quale è spesso ottenuta durante l'intervento chirurgico previa biopsia.

PAROLE CHIAVE: Orecchio medio • Tumore vascolare • Emangioma • Tumore glomico

Acta Otorhinolaryngol Ital 2011;31:109-112

Introduction

Haemangiomas are benign vascular lesions and they are very common in children and infants. They can occur in any region of the human body in which vasoformative tissue is represented¹. These lesions are relatively common in the head and neck district but they have rarely been reported in the middle ear².

Haemangiomas are usually present during the first month of life and they are characterized by a rapid growth period, defined proliferative phase, followed by a slow period of involution³. This behaviour differentiates these lesions from vascular malformations which are always present at birth, grow in proportion to the body and do not have an involution period⁴. Moreover, North et al., in a study, in 2000, emphasized that the haemangiomas, upon immuno-histochemical assessment, have been shown to stain positively for Glucose Transporter Protein Isoform 1 (GLUT-1) and Lewis Y antigen (LeY) in a sensitive and specific manner. This aspect seems to be typical of these tumours since the vascular malformations have not shown the same positivity to GLUT-1 and to LeY⁵.

Since middle ear haemangiomas are rare, little has been

published in the Literature regarding their diagnosis and management and this may lead to confusion in choosing an appropriate therapeutic strategy. However, haemangiomas must be considered in the differential diagnosis of any vascular lesion, above all of glomus tumour which is the most frequent vascular mass of the middle ear⁶ with a clinical presentation similar to that of haemangioma.

In this report, a case of haemangioma involving the middle ear, in a 77-year-old male is presented and the correct diagnosis and management of this rare lesion are discussed.

Case report

Herein, the case is described of a 77-year-old Caucasian patient, a pacemaker bearer, who came to our attention with a 10-year history of bilateral fullness and hearing loss which were more marked in the right ear. The clinical history was positive for an episode of right aural bleeding which had occurred the previous year. He did not complain of either vertigo or pulsatile tinnitus. There were no signs of facial nerve dysfunction.

Otomicroscopic examination revealed a reddish-blue

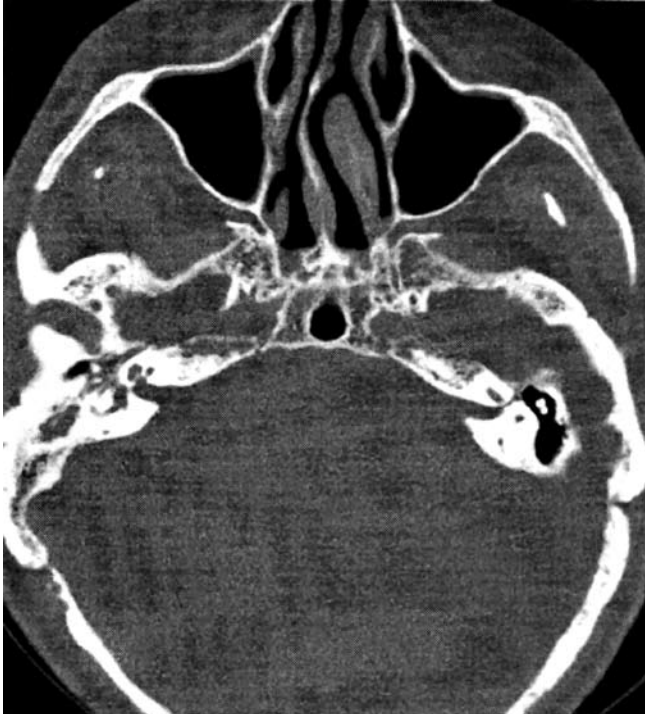


Fig. 1. Axial CT showed a low-density mass completely occupying the mastoid and the right middle ear with no signs of erosion of the ossicular chain.

compressible retro-tympanic mass in the right mesotympanum and hypotympanum.

A pure tone audiogram (PTA) revealed a moderate to severe mixed right hearing loss (PTA = 80 dB).

A non-contrasted multi-slice computed tomography (CT) showed a low-density area completely occupying the mastoid and the right ear with no signs of erosion of the ossicular chain (Fig. 1).

Unfortunately, the clinical history of the patient does not allow us to refer the patient for magnetic resonance imaging (MRI) examination.

Since a glomus tumour was suspected, a standard retro-auricular approach to the middle cavity was adopted, where a violet multi-lobulated mass, completely occupying the middle ear and mastoid cavity, was identified (Fig. 2). No deficits in continuity and mobility of the ossicular chain were recognized. Granulation tissue was present in the *sinus tympani* and facial recess. No signs of erosion of the fallopian canal were found at surgery.

An intra-operative biopsy ruled out a glomus tumour, in the differential diagnosis, suggesting the presence of a vascular malformation or haemangioma.

A canal wall up tympanoplasty was then performed which allowed, macroscopically, radical resection of the lesion (Fig. 3).

The histological examination revealed aggregates of capillary micro-vessels in a lobular arrangement. Architecture of blood vessels showed that they were incomplete and were surrounded by hyperplastic cells. These aspects, together with the positivity to GLUT-1 at the immuno-histochemical evaluation, confirmed the diagnosis of capillary haemangioma.

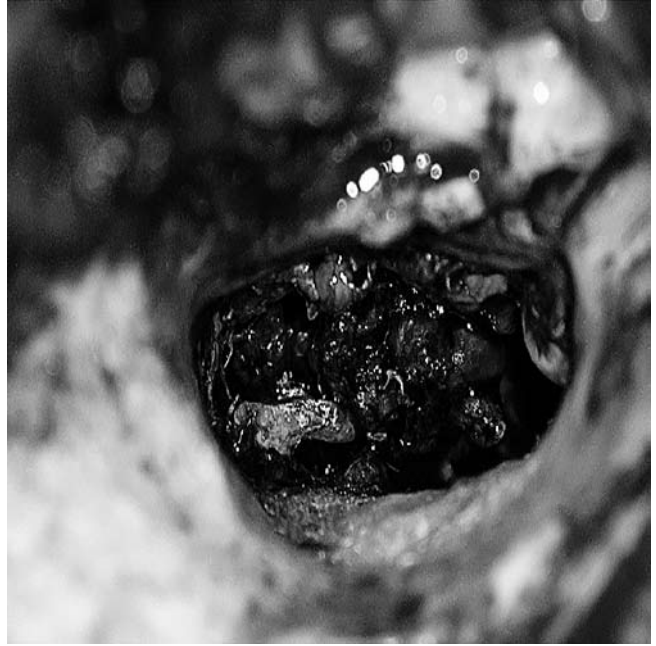

Fig. 2. Intra-operative view: a violet multilobated mass involved the middle ear but the ossicular chain was intact.



Fig. 3. The lesion was totally removed after a canal wall up tympanoplasty.

The post-operative course was uneventful and post-surgical audiometry examination showed resolution of the air bone gap (PTA = 45dB). The patient is still free of disease at 3 years' follow-up.

Discussion and conclusions

Haemangiomas are benign vascular tumours relatively common in the head and neck district but very rare in the

temporal bone. In 1981, Mangham et al. showed that, in a retrospective review of 1430 intra-temporal tumours, only 3 were haemangiomas (0.21%)⁷. The most frequent sites of occurrence are the geniculate ganglion region, the distal portion of internal auditory canal and the mastoid segment of the facial nerve⁶. Since 2000, only 7 haemangiomas of the middle ear have been published in the Literature¹⁸⁻¹¹, for a total of 13 lesions reported.

Based on the Mulliken and Glowacki classification, approved by the International Society for the Study of the Vascular Anomalies, there are three variant forms of haemangioma: capillary, cavernous and combined¹². Capillary haemangioma consists of closely arranged capillary-like channels and it tends to be superficial in location, while the cavernous type is composed of large cavernous vascular spaces and it is deeper¹³. Combined haemangioma presents features of both the capillary and cavernous form; it usually originates from the papillary and reticular dermis of subcutaneous tissue¹⁴. This classification, although commonly used, is object of debate¹⁵. In fact, histological evaluation of cavernous haemangioma does not show the endothelial hyperplasia and an increase in mast cell number during the proliferative phase, followed by fibrosis, fatty infiltration, decreased cellularity and normalization of mast-cell number during the involution period. It therefore follows that cavernous haemangiomas are more like vascular malformations and represent errors in morphogenesis rather than proliferative cellular processes. Conversely, the capillary form, in our patient, represents a true haemangioma with a typical histological feature characterized by the proliferative and involution phase. Recently, Buckmiller, in a 2010 review, referring to North's study, pointed out that only immuno-histochemical staining of GLUT-1 and LeY offers the possibility to identify a true haemangioma from a vascular malformation¹⁶. Positive GLUT-1 staining, seen in our tumour, confirmed the presence of a true haemangioma in our patient.

A variety of signs and symptoms have been reported for haemangiomas of the middle ear. They may be asymptomatic but the most common clinical manifestations are a retro-tympanic reddish-blue mass, accompanied by pulsatile tinnitus, hearing loss, aural bleeding, otorrhoea, vertigo and presence of a polypoid mass in the external auditory canal⁸. In fact, in our patient, the haemangioma caused an episode of otorrhagia associated with persistent hearing loss in the affected side, while otoscopy showed a typical retro-tympanic mass. Despite the fact that ac-

companying signs and symptoms are well known, they are common to nearly all vascular pathological conditions and this requires a correct differential diagnosis.

Glomus tumour is the most common vascular mass in the middle ear but other lesions should be included in differential diagnosis. In fact, a high jugular bulb, an aberrant intra-tympanic internal carotid artery, meningiomas and other tumours (e.g., rhabdomyosarcoma) and inflammatory processes, such as cholesterol granulomas and aural polyps, are some of the lesions that may mimic a haemangioma according to Dayal et al.¹⁷.

Pre-operative high-resolution CT is the procedure of choice for radiological evaluation¹⁸. Diagnosis can be obtained evaluating the size or the location site of the mass and the presence or absence of bone destruction. Middle ear haemangiomas appear radiographically as soft tissue densities with or without associated ossicular or bone erosion.

MRI and angiography or magnetic resonance angiography allow more definitive identification of the nature of a vascular mass in the middle ear. On MRI, T1-weighted images show a lesion of moderate intensity and T2-weighted images show a high intensity, while the tumour is clearly enhanced. Glomus tumour shows similar MRI features but sometimes in large masses multiple areas of slow and high signal intensity (so-called "salt and pepper") can be seen within the lesion⁶. Angiography shows a vascular blush similar to that of a glomus, but the stain associated with a haemangioma persists late into the venous phase whereas it dissipates rapidly in a patient affected by glomus tumour. In our case, the absence of bone destruction was evident on CT images but this has not enabled us to make a correct diagnosis while the clinical history of the patient does not provide MRI and angiography evaluation. However, the radiological features of haemangiomas can resemble many other middle ear lesions and they are not pathognomic.

In fact, definitive diagnosis can be obtained by exploration surgery, biopsy or excision of the mass and subsequent histological and immunochemical examinations^{19,20} such as in our patient.

In conclusion, we report on the fourteenth case of haemangioma of the middle ear and demonstrate that, although rarely, haemangioma can occur in the middle ear space.

Depending on its clinical presentation, this mass can be mistaken for other vascular masses such as glomus tumour or other lesions of the middle ear. Unfortunately, radiological evaluation can be insufficient to make a pre-operative diagnosis and the diagnosis is often based upon intra-operative biopsy.

References

- 1 Hecht DA, Jackson CG, Grundfast KM. *Management of middle ear hemangiomas*. Am J Otolaryngol 2001;22:362-6.
- 2 Manning SC, Culbertson MC, Vuitch F. *Bilateral middle ear*

lobular capillary hemangiomas. Otolaryngol Head Neck Surg 1990;102:85-8.

- 3 Waner M, Suen JY, Dinehart S. *Treatment of hemangiomas of head and neck*. Laryngoscope 1992;102:1123-32.
- 4 Jackson IT, Carreno R, Potparic Z, et al. *Hemangiomas,*

- vascular malformations and lymphovenous malformations: classification and methods of treatment.* *Plast Reconstr Surg* 1993;91:1216-30.
- ⁵ North PE, Waner M, Mizeracki A, et al. *GLUT1: a newly discovered immunohistochemical marker for juvenile hemangiomas.* *Hum Pathol* 2000;31:11-22.
- ⁶ Gulya AJ. *The glomus tumor and its biology.* *Laryngoscope* 1993;103:7-15.
- ⁷ Mangham CA, Carberry JN, Brackmann DE. *Management of intratemporal vascular tumors.* *Laryngoscope* 1981;91:867-76.
- ⁸ Tokyol C, Ylmaz MD. *Middle ear hemangioma: a case report.* *Am J Otolaryngol* 2003;6:405-7.
- ⁹ Davids T, Reid D. *Capillary hemangioma of the middle ear.* *J Otolaryngol* 2006;35:196-9.
- ¹⁰ Hsueh PJ, Chen WY, Chiang YC, et al. *Capillary hemangioma of the middle ear.* *Otolaryngol Head Neck Surg* 2007;136:666-7.
- ¹¹ Kojima H, Yaguchi Y, Moriyama H. *Middle ear hemangioma: a case report.* *Auris Nasus Larynx* 2008;35:255-89.
- ¹² Mulliken J, Glowacki J. *Hemangiomas and vascular malformations in infants and children: a classification based on endothelial characteristics.* *Plast Reconstr Surg* 1982;69:412-20.
- ¹³ Waner M, Suen JM. *A classification of congenital vascular lesions.* In: Waner M, Suen JM, editors. *Hemangiomas and vascular malformations of head and neck.* New York: Wiley-Lyss; 1999. p. 1-12.
- ¹⁴ Werner JA, Dunne AA, Folz BJ, et al. *Current concepts in the classification, diagnosis and treatment of hemangiomas and vascular malformations of the head and neck.* *Eur Arch Otorhinolaryngol* 2001;258:141-9.
- ¹⁵ Glasscock ME, Smith PG, Schwaber MK, et al. *Clinical aspect of osseous hemangiomas of the skull base.* *Laryngoscope* 1984;94:869-73.
- ¹⁶ Buckmiller LM, Richter GT, Suen JY. *Diagnosis and management of hemangiomas and vascular malformations of the head and neck.* *Oral Diseases* 2010;16:405-18.
- ¹⁷ Dayal VS, Lafond G, Nostrand V, et al. *Lesions simulating glomus tumors of the middle ear.* *J Otolaryngol* 1983;12:175-9.
- ¹⁸ Achilli V, Mignosi S. *Facial nerve hemangioma.* *Otol Neurotol* 2002;23:1002-3.
- ¹⁹ Buckmiller LM. *Updates on hemangiomas and vascular malformations.* *Curr Opin Otolaryngol* 2004;16:476-87.
- ²⁰ McKenna BM, North PE, McKenna MJ, et al. *Facial nerve hemangiomas: vascular tumors or malformations?* *Otolaryngol Head Neck Surg* 2010;142:108-14.

Received: April 5, 2010 - Accepted: July 11, 2010 - EPUB December 29, 2010